

ON THE EXTERNAL CHARACTERS OF FŒTAL REINDEER,  
AND OTHER NOTES.

BY R. W. SHUFELDT, M. D.

Mr. Lucien M. Turner, on the 20th of May, 1884, collected at Fort Chimo, Ungava District, Hudson's Bay, two specimens of fœtal Reindeer, or Woodland Caribou (*Rangifer tarandus caribou*, Kerr), one being a male and the other a female. They were taken from slain does, "one from each, and within eighteen days of delivery," and at once consigned to strong alcohol, the tank containing them being sent to the Smithsonian Institution at Washington. Early in February, 1886, Professor Baird sent them to the writer, then residing at Fort Wingate, New Mexico, for anatomical description; owing to the fact, however, that my investigations upon the osteology of arctic birds then engaged every moment of my available time, they were not examined until nearly the middle of June of the same year. Although they had been in spirit two years, they were found to be in excellent condition, and I at once made the drawing of the head of the male, which illustrates the present paper. As will be seen further on, the male fawn of this pair is somewhat larger than the female, with which it differs in several minor details other than those pertaining to the organs of sex.

The male subject I found to possess a very full coat of soft fine hair which completely covered its body, extending up to the lips and snout, and well inside of the external ears. In the median line in front, from below the jaw to the root of the neck, this hair is so long as to form a conspicuous beard, becoming longer as we proceed towards the last-named locality, where it is the best developed.

About the muzzle, this hair is of a dark blackish-brown color, which shades off as we advance towards the forehead, and again becomes darker around the eye.

The ears are completely covered with a coat of soft fur of a light brownish-clay color, darkest at their bases, and shading off toward their tips. The remainder of the hair of the head is of a fawn-brown, which color extends down on the neck, but as we come on to the body this changes to a dark chocolate-brown above, and a clay-colored brown on the lower parts and abdomen.

The limbs are of about the same shade as the back, and the tail, which is well developed, is dark above and lighter beneath. No pure white occurs upon either of the specimens.

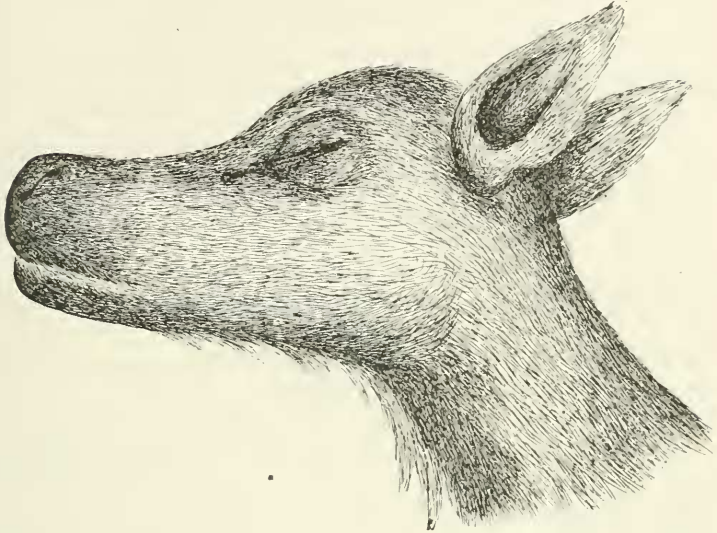

FIG. 1.

Left lateral view of the head of foetal Reindeer (*R. tarandus caribou*). A much reduced copy made by the author from his life-size colored figure.

Unfortunately, the eyes were found to be nearly destroyed for any purpose, and it was not only impossible to tell the color of the irides, but the long keeping had rendered them useless for anatomical description.

All of the hoofs were found to be fairly well developed, except at their antero-internal tips, where the horn-substance had been of such a delicate and elementary character as to have become quite shrunken and wrinkled by the action of the alcohol.

These remarks apply equally well to the condition of the hoofs of the posterior rudimentary digits, of which, as usual, there are two at the back of each foot.

Either external nostril is an aperture of considerable size, and viewed from above it is parallel to the longitudinal axis of the body, while seen upon lateral aspect it is oblique with its posterior commissure the higher.

Eyelashes are well pronounced on the eyelids, especially on the superior ones, being best developed on the middle of the lid, and becoming shorter as we proceed in the direction of either canthus.

A portion of the umbilical cord remains attached to either one of the specimens, but the placenta were not sent with them.

The theca of the penis is attached to the abdomen to within 4.4 centimetres of the umbilical cord, beyond which it is pendant, and in this young specimen was found to completely ensheath the organ which it contains. This theca is very well covered with rather long hair of a bright clay color.

At this age the testicles have not as yet descended and in the subject now under consideration, the scrotal sack is small and shrunken. All of the hoofs are of a clear horn color.

Caton found the "tarsal gland large" in the adult of this species, and says of it, that "on the Woodland Caribou, the tuft of hairs over the tarsal gland also has its characteristics, which enable one who has studied it to readily recognize it, though it is more variable in size and shape than on the moose."

"The hairs composing the tuft occupy a descending position. From the upper end the tuft commences to rise up gradually, and so continues to the lower end, where the elevation is greatest. The length of this tuft is two inches, while the breadth is one inch and three lines. The middle of this tuft is a yellowish-white, for a horizontal extent of two inches, and a vertical extent of one inch and three lines. The greatest diameter of the white portion is near the lower border of the tuft. Below the white portion the tuft shades down to the olive-brown of the rest of the leg. It occupies the internal cavity of the hoof posterior to the central part. It is not quite so large in proportion to the size of the animal as on most of the other species, neither is it much below them in relative size. It is not so exactly alike on each individual of this species as it is on the smaller species."<sup>1</sup>

<sup>1</sup> CATON, JOHN DEAN: *The Antelope and Deer of America*, New York, 1877, pp. 253-54. Mr. Caton in comparing the above condition of these glands with the European Reindeer found that they correspond in all essential particulars. In this connection I would like to say that at the time my dissections were made upon these fawns, my library and my facilities for consulting books were limited. Mivart's "Cat;" the works of Owen, Flower, Oldfield Thomas, Chauveau, Huxley, and a number of others were, however, in my field library. Doctor John Dean Caton was at that time in Monterey, California, and I wrote him for a copy of his excellent volume upon "The Antelope and Deer of America," just cited; and it is my desire to express to him here my grateful thanks for his having telegraphed to his son at his home in Chicago, with the effect of placing a gift of the volume very promptly in my hands for use.

This description answers very well indeed, for both the position and appearance of this tarsal gland and its tuft in the fœtus. Here, however, the gland is quite rudimentary and the tuft is proportionately smaller. The color of the hair seems to agree with Mr. Caton's description, also,—but so diminutive are these glands in this young subject, that little can be learned about them from the exterior, and a study of their internal structure falls within the domain of the histologist rather than that of the anatomist. I have failed to discover any metatarsal glands or inter-digital ones in this subject. The authority just quoted found them in the hind feet only, and if they are present in the fœtus in my hands, they are exceedingly rudimentary.

Mr. Caton calls attention, too, in the adult, to a white band surrounding the top of each hoof;—this is likewise absent in my specimens. The adults of this Caribou make considerable use of their accessory hoofs, and these are "subject to muscular control;" such a condition seems to be foreshadowed in the fœtus, especially in the feet of the anterior limbs, where the accessory hoofs are large and situated low down.

Previous to cutting down upon this specimen, (b) I made careful drawings of the tarsus and foot of the anterior and posterior limbs, together with the form of the tail; and these are here reproduced as drawings illustrating this paper. Passing next to the consideration of the female specimen we find that beyond the sexual differences as pertaining to the organs of reproduction, and being rather smaller in size, it presents us with no special departures in its general appearance, either as regards color or form, from the male just described. Perhaps the coat of the female may be a shade lighter, and the hair down the median line of the throat beneath is not quite so conspicuously long. The vulva and external genitals have advanced to a point of development that we might expect in a ruminant of this tender age, and offers nothing for special remark. It is fairly well covered by the tail.

Most fetal mammals at this age show a pre-natal emaciation, which, in these specimens, has been enhanced by the action of the alcohol upon their delicate tissues and muscles.

I did not think it necessary at the time to weigh either of these specimens, for the reason, that they were saturated by the alcohol, and that other changes must have taken place in them, which would render such data of but little or no use.

Such strictures, however, do not apply to careful measurements of external parts. Of these I have quite fully availed myself, and they are presented in the subjoined table.

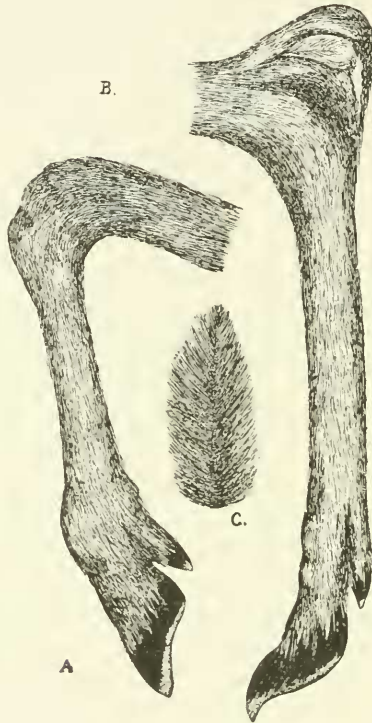


Fig 2-A. Inner aspect of the right tarsus, metatarsus and foot of the anterior limb of a foetal Reindeer (*R. tarandus caribou*).

B. Corresponding aspect and parts of the hinder limb; same specimen. The tarsal gland is here seen covered by its lighter colored tuft of hair.

C. Superior aspect of the tail of the same specimen. The under side of the tail in this foetus is of a light brownish fawn color, while above, it is rather of a chestnut shade. It is white on the lower side in the adult. Figures all drawn by the author from the subjects, and much reduced.

*Measurements of fetal specimens of R. tarandus caribou (Alcoholics, eighteen days prior to birth):—*

	MALE.	FEMALE.
	Cms.	Cms.
Total length including tail,	71.00	70.00
Girth immediately behind the arms,	35.00	32.00
Length of head,	17.00	16.8

Length of nostril,	2.00	2.00
Between the eyes,	9.5	9.2
Height of ear,	8.00	7.8
From anterior canthus of eye to tip of nose.	8.5	8.3
Between the ears,	5.00	5.00
Girth of middle of neck,	16.00	15.3
Length of tail,	8.2	7.2

All the measurements were taken previous to making any of the dissections. Other things being proportionately equal it will be observed that "girth of neck" and "length of tail" constitute the greatest differences.

#### MYOLOGICAL NOTES.

A complete dissection of the muscular system of these fawns was not made by me for the reason, or rather reasons, that my labors at the time were cut short by the operation of certain laws or customs to which I was subservient, and over which I had no personal control, and, which, at the same time, were hostile to the prosecution of researches in anatomy. In the meantime, and at a later period, this material passed out of my hands, as more general work engaged me, and I returned it to the Museum. The description of such muscles as I was enabled to work out, however, is fully worthy of record as so many facts for the guidance of laborers in the same fields in the future. Moreover, reindeer are being rapidly exterminated, and any notes upon their morphology are sure to be of value in time to come.

*Dermal System of Muscles.*—In this fetal specimen the group of cutaneous muscles, whose function it is to act upon and agitate the skin covering certain areas of the body, are as yet but feebly developed.

We can make out, however, without difficulty the following:—

The *platysma myoides* is quite conspicuously developed, being carried on the skin over the sides of the face as far forwards as the nasal region where, no doubt, it assists in the twitching movements of the skin about the nose.

In the mid-anterior region of the neck it becomes quite thick, especially in the line of integument which supports upon its outer aspect the elongated hair there found in this animal.

Its fibres become very pale as they spread out over the dorsal aspect of the neck, and the entire muscle is lost and fades away as we pass to the region of the shoulders and upper thoracic area.



The *panniculus carnosus*, or that great muscular envelope the function of which is to act upon the integuments of the entire trunk, is here but moderately displayed. I dare say, though, that in the adult reindeer this interesting muscle will be found fully as well developed as it has been described by several anatomists of the horse, and by others in the *Felidæ*.

In this fœtus it is best marked where it is intimately attached to the lateral integuments of the thorax and abdomen, and over the abdomen itself.

In the median line from a short distance in front of the umbilicus to a point well upon the sternum, it arises from a thin fascia more or less intimately connected with the skin by its outer surface, and to the external oblique by its inner. Posterior to this, the fibres are in the skin, and radiate from the periphery of a circle surrounding, but lying without, the umbilicus. The posterior border of the muscle is thick and extends toward the thigh, while for the rest, the fibres spread out, closely connected with the skin, over the sides of the lower thoracic region and the abdomen, and the lateral aspects of the thigh. It does not seem to meet, in this young subject, the fellow of the opposite side along the dorsum. But from its rounded carneous margin, the fibres appear to merge into a delicate fascia, which extends over this region and down the sides of the thigh. In the integuments overlying the sacral area, however, the carneous fibres appear again, and can be faintly traced as far as the root of the tail.

Chauveau in describing the *panniculus carnosus* of the horse, says: "This muscle has, besides, a very remarkable insertion into the humerus, which was noticed by G. Cuvier in his 'Leçons d'Anatomie comparée,' and which appears to have been omitted, at least so far as Solipeds are concerned, in every treatise on veterinary anatomy. The following is what we have often observed in this respect: On reaching the posterior border of the ulnar mass of muscles, the panniculus divides into two superposed layers; one, superficial, is carried to the muscles of the anterior member; the other, deep, soon terminates by an aponeurosis which is united to the great pectoral muscle, and is bordered at its upper margin by a nacreous aponeurotic band, which penetrates between the thorax and the muscles of the arm to be fixed to the small trochanter."<sup>1</sup>

<sup>1</sup> CHAUVEAU, A. The Comparative Anat. of the Domesticated Animals, 2nd Ed. 1884, N. Y.; trans. and ed. by G. Fleming, p. 187.

A very similar arrangement I find to exist in this foetal reindeer, but it seems to me that the dermal system can only claim that layer which is here confined to the skin, and which by its fascial extensions it has the power of twitching over the anterior and upper part of the chest and on the fore-limb. Intimately connected with this, and with the great pectoral over which it lies, is, to be sure, another layer that here seems to be entitled to rank with the more important muscles of the front of the chest. It arises from the fascia over the median line of the sternum, and is closely connected with the skin above, which covers it. We find its insertion, however, not upon the small trochanter, but upon the shaft of the humerus, at the interno-anterior aspect of the summit of its distal third, above the internal condyle. Before arriving at the point of insertion, the fibres of the muscle converge to form a flattened fasciculus, which passes down between the muscles of the arm. Undoubtedly by its contraction this muscle can, in connection with the true dermal layer alluded to above, and with which it is associated, act upon the skin of these parts, but I am strongly inclined to believe that it represents one of the pectoral muscles as they have been described in the cat.

Mivart in his anatomy of this animal, divides the *pectoralis* into five portions, and of the insertion of the second portion he says, "It is inserted into the outer side of the deltoid ridge of the humerus, and extends down (between the biceps and brachialis anticus) to the summit of the lowest third of the humerus." In this reindeer the outer margin of this muscle for its proximal two-thirds is attached to the fascia dividing the muscles at the inner side of the brachium.

It is very evident that in the adult this muscle will act powerfully both on the humerus and the anterior chest walls, while, when the animal stands at rest, the action of its more superficial fibres can be made to agitate the integuments of the parts. Be this as it may, I will not enter upon a second description of the muscle here, though I think strictly speaking it should be regarded as an auxiliary pectoral, and not as one of the dermal system proper.

*Of Certain Muscles of the Head.*—Considering the tender age of the subject before us, the musculature of the ear, eye, mouth, and face is very well developed.

---

<sup>1</sup> MIVART ST. GEORGE, F. R. S. The Cat, New York, 1881, page 145. This work I find to be an exceedingly useful one to those engaged upon dissections of the Mammalia.



The *myrtiformis* muscle seems to be unusually large, and of an irregular quadrilateral form. It arises from the side of the nostril, and being firmly connected with the skin, its fibres descend downward and backward to be lost in the dense tissues of the upper lip.

The *orbicularis oris* is, as a sphincter of the mouth or lips, a very feebly developed muscle here, and great care is required, to trace its delicate fibres in the tissues where they lie hidden.

The *levator labii superioris atque nasi* on the other hand is perhaps the most conspicuously developed of all the facial muscles in this young deer. It arises from the malar and superior maxillary bones, and its fibres forming a strong flat muscle, pass directly forwards, closely connected with the integument, and above the alveolar process of the upper jaw, to become blended with the fibres of the *orbicularis oris* in the upper lip, and are lost upon the ala of the nostril.

The *orbicularis palpebrarum* is also pronounced, but presents us with nothing peculiar, or any marked departure from that muscle as we find it among the deer generally. I have, however, failed to make out satisfactorily an *occipito-frontalis*, a *levator anguli oris*, a *pyramidalis*, and a number of other less important muscles of the face. In the adult, where through use they had become more clearly defined, no doubt a number of them could be traced, and I see that Professor Mivart has worked them out in an admirable manner in the cat, but they need not further concern us here.

The musculature of the eye and ear, is, considering the age of the specimen, very completely advanced, and I suspect strongly developed in the case of the former structure in adult life.

The *Attolentes auriculum* are a handsomely developed pair of muscles that nearly meet each other on the median line of the skull between the external ears. By their action these appendages of the organ of hearing may be powerfully drawn toward each other.

A strong *zygomo-auricularis* is also seen as we remove the integuments of the head. It arises from the zygoma, and passing backwards and upwards is inserted upon the outer aspect of the pinna.

Other representations of the group of muscles that control the varied movements of the external ear are easily traced, and in most cases well defined.

A *buccinator* can be made out as we trace its delicate fibres in the sides of the lips, and as far back as the alveolar processes of the jaws extend.

As usual in mammals, the *masseter* is divided in two layers, the fibres of the outer one passing obliquely backwards, while those of the deep portion being more or less vertical.

The muscle arises from the zygoma for its infero-anterior portion, and from the malar bone. Passing down in a way already indicated, they become inserted into the outer aspect of the ascending ramus of the lower jaw, completely filling the concavity there existing.

A *temporal muscle* is no larger, if as large, as the *masseter*. Either one fills the shallow temporal fossa at the side of the skull, and measuring the distance between their nearest points to each other, over the vault of the skull, with a flexible tape measure, I find them to be separated by an interval of seven centimetres. The tendon of a temporal is inserted as usual into the coronoid process of the mandible, entirely upon its mesial side.

The *pterygoids* are well-developed muscles, but present nothing worthy of especial note in these fetal specimens of our reindeer.